

## Acetabular Labral Tears of the Hip: Examination and Diagnostic Challenges

RobRoy L. Martin, PT, PhD, CSCS<sup>1</sup>

Keelan R. Enseki, PT, MS, ATC, SCS, CSCS<sup>2</sup>

Peter Draovitch, PT, MS, ATC<sup>3</sup>

Talia Trapuzzano, DPT, ATC, CSCS<sup>4</sup>

Marc J. Philippon, MD<sup>5</sup>

The purpose of this clinical commentary is to provide an evidence-based review of the examination process and diagnostic challenges associated with acetabular labral tears of the hip. Once considered an uncommon entity, labral tears have recently received wider recognition as a source of symptoms and functional limitation. Information regarding acetabular labral tears and their association to capsular laxity, femoral acetabular impingement (FAI), dysplasia of the acetabulum, and chondral lesions is emerging. Physical therapists should understand the anatomical structures of the hip and recognize how the clinical presentation of labral tears is difficult to view isolated from other hip articular pathologies. Clinical examination should consider lumbopelvic and extra-articular pathologies in addition to intra-articular pathologies when assessing for the source of symptoms and functional limitation. If a labral tear is suspected, further diagnostic testing may be indicated. Although up-and-coming evidence suggests that information obtained from patient history and clinical examination can be useful, continued research is warranted to determine the diagnostic accuracy of our examination techniques. *J Orthop Sports Phys Ther* 2006;36(7):503-515. doi:10.2519/jospt.2006.2135

**Key Words:** diagnosis, labrum, MRI

There is growing interest in musculoskeletal-related hip disorders associated with the evolution of hip arthroscopy. New and interesting information regarding both intra-articular and extra-articular pathologies is being made available.<sup>12,51,68</sup> Most notably is the identification of acetabular labral tears and their association to capsular laxity, femoral acetabular impingement (FAI), dysplasia of the acetabulum, and chondral lesions. FAI is one area we are beginning to understand as emerging research becomes available. For the hip region, the relationship of anatomical pathology to signs, symptoms, and functional limitation is not well

understood. The lack of a clear relationship makes it important for physical therapists to have a sound understanding of the anatomical structures of the hip and the ability to recognize how the clinical presentation of hip labral tears is difficult to view in isolation from other hip articular pathologies.

### ANATOMICAL CONSIDERATIONS

The labrum of the hip, to a large extent, is analogous to the meniscus of the knee and the labrum of the glenohumeral joint. It enhances joint stability, decreases force transmitted to the articular cartilage,<sup>27,28,68</sup> and provides proprioceptive feedback.<sup>27,28,37,70</sup> Nerve endings within the labrum not only provide proprioceptive feedback but can also be a source of pain.<sup>37</sup> The hip is intrinsically stable because of the deeply recessed acetabulum. If the acetabulum is abnormally shallow, there will be increased stress on the surrounding capsule and labrum. The labrum enhances joint stability not only by deepening the acetabulum but also by acting as a seal to maintain negative intra-articular pressure.<sup>70</sup>

The joint capsule is supported by 3 extra-articular ligaments. The pubofemoral, ischiofemoral, and iliofemoral ligaments support the

<sup>1</sup> Assistant Professor, Department of Physical Therapy, Duquesne University, Pittsburgh, PA.

<sup>2</sup> Staff Physical Therapist, Centers for Rehab Services, University of Pittsburgh Center for Sports Medicine, Pittsburgh, PA; Department of Physical Therapy, University of Pittsburgh School of Health and Rehabilitation Sciences, Pittsburgh, PA.

<sup>3</sup> Staff Physical Therapist, Centers for Rehab Services, University of Pittsburgh Center for Sports Medicine, Pittsburgh, PA.

<sup>4</sup> Staff Physical Therapist, Drayer Physical Therapy Institute, Harrisburg, PA.

<sup>5</sup> Orthopaedic Surgeon, Steadman Hawkins Clinic, Steadman Hawkins Research Foundation, Vail, CO. Address correspondence to RobRoy Martin, Duquesne University, Department of Physical Therapy, 114 Rangos School of Health Sciences, Pittsburgh, PA 15282. E-mail: [martinr280@duq.edu](mailto:martinr280@duq.edu)

joint inferiorly, posteriorly, and anteriorly, respectively. These ligaments are taut in extension and relaxed in flexion. Additionally, the iliofemoral ligament tightens during hip external rotation and adduction, the ischiofemoral ligament tightens during internal rotation and abduction, while the pubofemoral ligament tightens during external rotation and abduction. Traditionally it was thought that laxity of these ligaments occurred only as a consequence of macrotrauma. However, labral tears and microtrauma associated with repeated forced hip rotation may also be linked to capsular laxity.<sup>63,64,68</sup>

The ligamentum teres runs from the acetabular notch to the fovea capitis of the femur. Recent information suggests it has a role in stabilizing the hip and, when injured, it can contribute to symptoms.<sup>15,65</sup> The ligamentum teres tightens during adduction, flexion, and external rotation. Because of its redundancy, pinching between the femoral head and acetabulum can occur, causing complaints of pain and clicking. Partial tears may contribute to patient pain complaints.<sup>15</sup> A lesion of the ligamentum teres was the third most common finding in athletes undergoing arthroscopic surgery.<sup>13</sup> Patients with complete tears can report symptoms of joint instability in addition to complaints of pain.<sup>36</sup> Complete ruptures of the ligamentum teres have been associated with degenerative arthritis and avascular necrosis.<sup>65</sup>

The articular cartilage is thicker anterosuperiorly, where maximum weight bearing and stress occur. Articular cartilage lesions of the hip have usually been associated with progressive joint degeneration occurring with either osteoarthritis or rheumatoid arthritis.<sup>36</sup> However, recent arthroscopic evidence found anterosuperior acetabulum chondral lesions commonly occur with labral tears, FAI, and anterior capsular laxity.<sup>55</sup> Also, large lateral impact forces to the greater trochanter can result in a chondral lesion to the femoral head and acetabulum.<sup>36</sup>

Recently, there has been increased interest in acetabular labral tears. Once considered an uncommon entity, labral tears as a source of symptoms and functional limitation in the hip region have become more recognized. A labral tear was arthroscopically identified in 90% of individuals with mechanical hip symptoms.<sup>29,55</sup> However, isolated labral tears occur in only 5% of cases and are usually related to trauma.<sup>51</sup> Labral tears are commonly associated with FAI,<sup>5,42,71</sup> capsular laxity,<sup>62,63</sup> articular cartilage degeneration,<sup>55</sup> and dysplasia.<sup>25,31,55,59</sup> Although we are learning more about individuals who present with a potentially symptomatic labral tear, further research is needed to determine the prevalence of these disorders in asymptomatic individuals. It is quite possible that these lesions are present in asymptomatic individuals and, therefore, we need to be cautious and guard against overinterpreting these pathologies as the source of hip pain in patient populations.

## ETIOLOGY OF LABRAL TEARS

### Traumatic Injuries

The labrum, because of its function in distributing weight-bearing forces, is susceptible to traumatic injury from shearing forces that occur with twisting, pivoting, and falling. Because the labrum has free nerve endings, an isolated labral tear can result in pain production.<sup>37</sup> In the North American population the majority of tears are located anterosuperiorly and are often associated with sudden twisting or pivoting motions.<sup>3,24,29</sup> In contrast, in the Asian population the majority of tears are located posteriorly and are associated with hyperflexion or squatting motions.<sup>52</sup> Labral tears can lead to disruption of joint stability, causing abnormal motion between the femur and acetabulum. This abnormal movement can lead to labral fraying and chondral degeneration.<sup>41,55</sup>

### FAI

FAI occurs when there is decreased joint clearance between the femur and acetabulum. Cam and pincer are the 2 types of FAI described.<sup>42</sup> Cam impingement occurs when the femoral head has an abnormally large radius, with a loss of the normal spherical junction between the femoral head and neck. This deformity causes abnormal contact between the femur and acetabulum, particularly when hip flexion is combined with adduction, and internal rotation.<sup>34,60</sup> The cam impingement has been implicated in the etiology of anterosuperior labral and chondral lesions.<sup>4,28,33,44,45</sup> An abnormal acetabulum with increased overcoverage causes a pincer impingement.<sup>5,42,42</sup> This overcoverage can be general (coxa profunda) or local anterior (acetabular retroversion). Both types of overcoverage will cause persistent abutment of the femoral head into the acetabulum leading to 'contre-coup' posteroinferior chondral lesions.<sup>4,42</sup> Pincer impingements are thought to be more common in middle-aged women participating in athletics, while cam impingements are more common in young athletic males.<sup>42</sup> Similar impingement problems have been recognized after hip replacement.<sup>32,40,76</sup> There is evidence that these types of FAI can not only cause labral tears but also bring about a progressive degenerative process leading to osteoarthritis.<sup>4,27,28,30,33,34,39,44-46,71</sup>

### Capsular Laxity

While traumatic hip subluxation and dislocation are known to cause capsular laxity at the hip,<sup>22,47,66</sup> there is less information regarding atraumatic capsular laxity. Atraumatic laxity can be divided into 2 groups: (1) global and (2) focal rotational.<sup>68</sup> Global laxity occurs in individuals with connective tissue

disorders (ie, Down's, Marfan's, and Ehlers-Danlos syndromes). Focal rotational laxity is a recently recognized entity and typically results from excessive forceful hip external rotation. These forces are known to occur in sports such as golf, ballet, gymnastics, martial arts, hockey, and baseball.<sup>63,68</sup> Forced hip external rotation can lead to iliofemoral ligament insufficiency. Although uncommon, repeated, forced hip internal rotation can lead to insufficiency of the ischiofemoral ligament. When insufficiency is present, the ligament's ability to absorb stress is compromised, potentially subjecting the labrum to abnormal stress and pathology.<sup>63</sup>

A labral tear can also contribute to capsular laxity. When a labral tear is present, its ability to act as a buttress to prevent movement and to act as a seal to maintain negative intra-articular pressure may be compromised.<sup>21,63</sup> Increased stress will be transferred to the ligaments that support the hip, particularly the iliofemoral ligament. Over time, this increased stress may promote anterior capsular laxity, especially if one is engaging in activities that involve forceful hip external rotation. The capsule and labrum are load-bearing structures; therefore, a labral tear and capsular laxity can potentially lead to complaints of instability.<sup>62,63</sup>

## Dysplasia

Developmental dysplasia of the acetabulum is defined by a shallow acetabular socket.<sup>25,55</sup> This shallow acetabular recess results in decrease coverage of the femoral head anteriorly and laterally, compromising the normal bony stability of the hip.<sup>75</sup> Increased stress on the anterior joint capsule and labrum will result from this deformity.<sup>7</sup> Over time, this increased demand on these structures for maintaining stability can contribute to hypermobility and labral tears.<sup>14,25,55,59</sup> McCarthy et al<sup>55</sup> reported that 15% (76 out of 436) of his hip arthroscopic cases had dysplasia, with 49% having anterior and 4.5% having posterior labral tears.

## CHONDRAL LESIONS

Labral tears have been implicated in the degeneration of the acetabular articular surface. McCarthy et al<sup>55</sup> reported that 73% of patients with labral pathology have chondral damage. The absence of an intact labrum causes increased contact pressure and articular cartilage consolidation.<sup>27,28</sup> Anterosuperior chondral damage has been associated with cam FAI, anterior capsular laxity, and dysplasia.<sup>42,45,59,63</sup> Dysplasia, labral tears greater than 5 years in duration, and full-thickness chondral lesions have been implicated in the progression of osteoarthritis.<sup>53,56</sup>

## TYPES OF LABRAL TEARS

Labral tears have been classified into 4 types: radial flap (Figure 1), radial fibrillated (Figure 2), longitudinal peripheral (Figure 3), and abnormally mobile (Figure 4).<sup>41</sup> Lage et al<sup>41</sup> found that radial flap tears were the most common type and defined them as having a disruption of the free margin of the labrum. Radial fibrillation involves fraying of the free margin and was associated with degenerative joint disease.<sup>41,55</sup> Abnormally mobile tears can result from a detached labrum, similar to a Bankart lesion in the shoulder. The least common type were tears occurring in a longitudinal direction in the peripheral aspect of the labrum.<sup>41</sup> Labral tears most commonly occur in an anterior and anterosuperior location on the inner aspect of the labrum.<sup>5,41,55</sup> In addition to classifying the tears as described above, McCarthy et al<sup>53</sup> have outlined a different classification that describes the location and size of the articular cartilage lesions that occur with a labral tear.

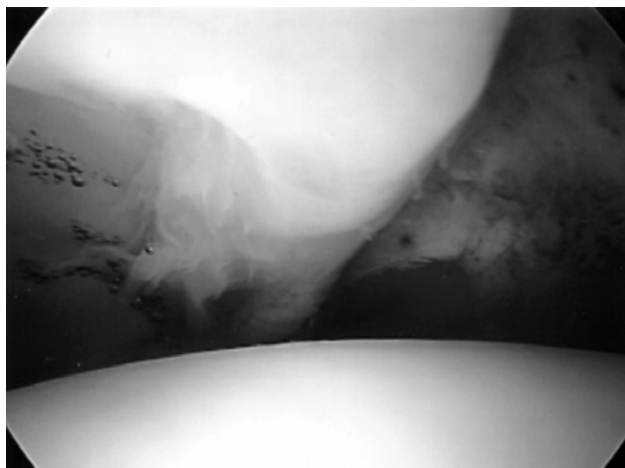
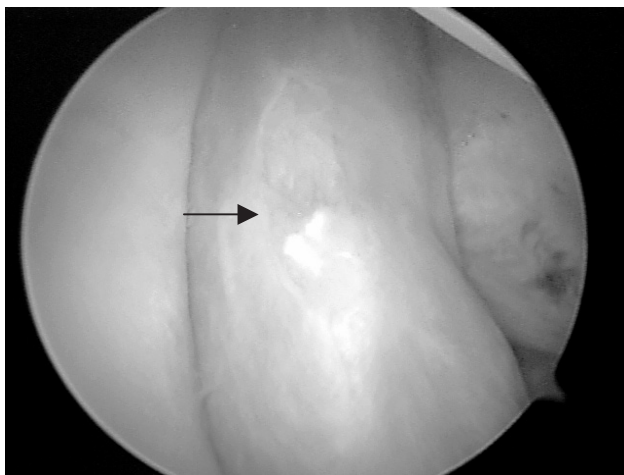


FIGURE 1. Radial flap tear of the acetabular labrum as seen during arthroscopic hip surgery.

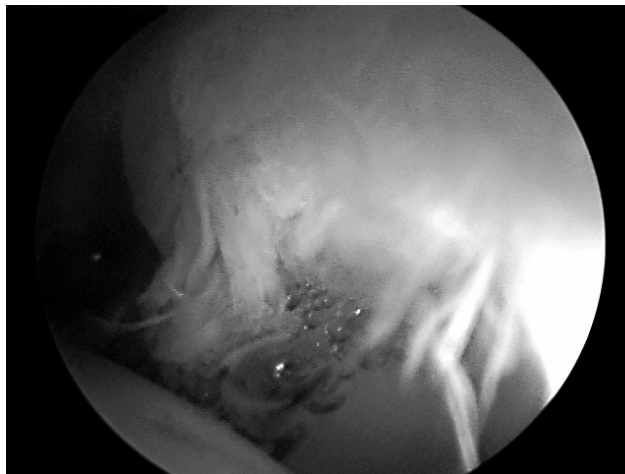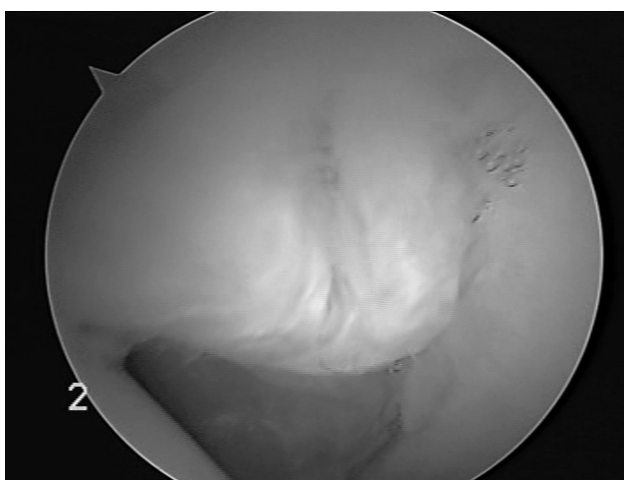


FIGURE 2. Radial fibrillated tear of the acetabular labrum as seen during arthroscopic hip surgery.





**FIGURE 3.** Longitudinal peripheral tear of the acetabular labrum as seen during arthroscopic hip surgery.



**FIGURE 4.** Abnormally mobile tear of the acetabular labrum as seen during arthroscopic hip surgery.

## CLINICAL ASSESSMENT

While there is some evidence that anatomically relates labral tears to trauma, FAI, capsular laxity, dysplasia, and chondral lesions, there is less evidence regarding the usefulness of symptoms, signs, and clinical examination in detecting labral tears. It is generally believed, however, that the most important part of diagnosing hip pain is the history and clinical exam.<sup>12,54</sup>

### Injury Mechanism

A traumatic event can precipitate a labral tear. The most common mechanism of injury is felt to be an external rotation force in a hyperextended position.<sup>52</sup> However, a distinct traumatic event related to the onset of symptoms may not be reported by most patients.<sup>5,41,57,58,71</sup> Alternately, the mechanism of injury may be related to repetitive microtrauma associated with repeated pivoting and twisting.<sup>55</sup> When

symptoms are microtraumatic in origin, we have the patient describe the motion that reproduces the symptoms to help identify the tissues that are under strain.

## History and Symptoms

Symptoms associated with a labral tear can include pain, clicking, locking, catching, instability, giving way, and/or stiffness. It has been reported that intra-articular hip pathologies can refer pain to the anterior groin, buttock, greater trochanter, thigh, and/or medial knee.<sup>36</sup> A labral tear is thought to commonly refer pain to the anterior groin region. Keeney et al<sup>35</sup> and McCarthy and Busconi,<sup>54</sup> respectively, reported that 96% and 100% of individuals with an arthroscopically identified labral tear reported groin pain. However, McCarthy and Busconi<sup>54</sup> did not find a correlation between labral tears and anterior groin pain ( $r = 0.16$ ,  $P = .41$ ). In this study, the overall prevalence of anterior groin pain for individuals with other sources of intra-articular hip pathology was 98%. From the information available, it seems that complaints of groin pain may not be specific to labral tears but may be due to other intra-articular pathologies as well.

Posterior buttock pain is thought to be more common with lumbosacral spine pathology or posterior hip musculature injuries. Lateral hip pain is thought to be more common with trochanteric bursitis and/or iliotibial band syndrome, while thigh pain is more commonly attributed to degenerative joint disease.<sup>50</sup> This is consistent with our experience. However, a labral tear may also cause posterior and/or lateral hip pain in addition to groin pain. In the Keeney et al<sup>35</sup> study, 34% of individuals with diagnosed labral tears complained of anterior thigh pain, 38% complained of lateral hip pain, and 17% complained of buttock pain. McCarthy and Busconi<sup>54</sup> found medial thigh pain correlated to degenerative hip arthritis ( $r = 0.46$ ,  $P = .002$ ).

In addition to pain, labral tears can also cause mechanical symptoms such as clicking, giving way, locking, and catching. Keeney et al<sup>35</sup> documented that 58% of individuals with a labral tear reported hip locking or catching. McCarthy and Busconi<sup>54</sup> found that painful inguinal clicking and giving way significantly correlated to labral tears ( $r = 0.79$ ,  $P < .0005$  and  $r = 0.41$ ,  $P < .002$ , respectively). In the study by Narvani et al,<sup>58</sup> clicking had 100% sensitivity and 85% specificity for a labral tear identified by magnetic resonance arthrogram (MRA). Based on the information provided in the article by Narvani et al,<sup>58</sup> we calculated the positive likelihood ratio for the presence of clicking in determining the presence of a labral tear to be 6.67.

Intra-articular clicking should be carefully distinguished from extra-articular iliopsoas or iliotibial band snapping. In our experience, clicking that occurs with hip internal and external rotation is most likely from a labral tear; however, published clinical research on this is lacking. Extra-articular snapping that occurs laterally when the hip is flexed from an extended position can be caused by the iliotibial band snapping over the greater trochanter. The iliopsoas tendon can snap over the iliopectineal eminence or femoral head as the hip moves from flexion to extension.<sup>23,67</sup>

While anterior groin pain, intra-articular clicking, and giving way is thought to result from labral tears, symptoms associated with FAI, capsular laxity, and degenerative changes should also be recognized. We have found that FAI can produce anterior pinching pain with sitting, while laxity can produce a sense of hip instability. External rotation at the hip that occurs with activities such as swinging a golf club may precipitate a sense of instability when iliofemoral ligament laxity is present.<sup>36</sup> Complaints of morning stiffness can be helpful in identifying individuals with hip osteoarthritis.<sup>2</sup> We have found anterior pinching pain that occurs with sitting, feeling of instability, and morning stiffness to be useful in differentiating among FAI, capsular laxity, and osteoarthritis.

### Physical Examination

There is little information regarding the sensitivity, specificity, or likelihood ratios associated with a single clinical test or a cluster of tests in diagnosing a labral tear. Most of the tests described provide more general information regarding the potential for lumbosacral spine, intra-articular, and/or extra-articular hip pathology.

### Examination for Intra-articular Hip Pathology

A number of clinical tests may be useful to assess for intra-articular lesions. In addition to labral tears, these pathologies include chondral lesions, osteoarthritis, synovitis, loose bodies, avascular necrosis, osteonecrosis, and/or inflammatory arthritis. Tests for intra-articular lesions include the FABER or Patrick test, scour test, and the resisted straight leg raise test. The FABER test involves combining the motions of hip flexion, abduction, and external rotation.<sup>49</sup> Two components of the FABER test that require evaluation are pain provocation and range of motion. Reproduction of pain itself is not a positive test for intra-articular hip pathology, as the clinician must inquire about the location of pain. In our experience, posterior hip pain may be indicative of

sacroiliac joint involvement, while anterior hip/groin pain may indicate an intra-articular hip pathology. Side-to-side range of motion differences are assessed by measuring the distance from the knee to the table. We believe that a decrease in range of motion on the involved side may indicate either capsular tightness or psoas spasm. Mitchell et al<sup>57</sup> reported that hip pain during the FABER test was 88% sensitive for intra-articular hip pathology. This study did not find a correlation between a positive FABER test and specific hip pathology.

In addition to the FABER test, we use the Scour test and resisted straight leg raise. The Scour test involves passively moving the femur through an arc of motion incorporating hip flexion/adduction and extension/abduction.<sup>49</sup> During the movement a compressive force is applied to the joint, while the leg is moved clockwise and counterclockwise. The test assesses for reproduction of hip pain and/or intra-articular joint clicking. The resisted straight leg raise test is felt to load the joint anterosuperiorly and to reproduce anterior groin pain when an intra-articular lesion is present.<sup>36</sup> The test is performed with the patient supine. The lower extremity is actively raised to approximately 30° of hip flexion with the knee in full extension. The patient is then asked to hold the lower extremity at that angle while the examiner applies resistance to the anterior thigh just proximal to the knee. In our experience, the scour and resisted straight leg raise tests may also apply strain to the lumbosacral area. Therefore, we feel it is important to identify the location of symptoms as being the hip or lumbosacral region. The FABER, Scour, and resisted straight leg raise tests assess for the presence of intra-articular lesions. Therefore, a positive test may indicate not only the presence of a potential labral tear but other intra-articular pathologies as well.

When the history, symptoms, and signs are consistent with a labral tear, we assess for potential associated factors such as FAI, capsular laxity, and articular cartilage degeneration. In this regard, we use impingement tests, the log roll test, long-axis femoral distraction, tests for general ligament laxity, and hip range-of-motion assessment to distinguish among these disorders. In our experience we find these tests useful; however, published clinical research is needed.

Impingement tests have been described as being used to assess for FAI.<sup>48</sup> The most common test involves the combined motions of hip flexion, internal rotation, and adduction (Figure 5).<sup>44</sup> This combined movement engages the femoral head-neck junction into the anterior superior labrum and acetabular rim.<sup>43</sup> This test is similar to that described by Fitzgerald.<sup>29</sup> During surgery, Beck et al<sup>5</sup> demonstrated that impingement occurs at 80° to 90° of hip

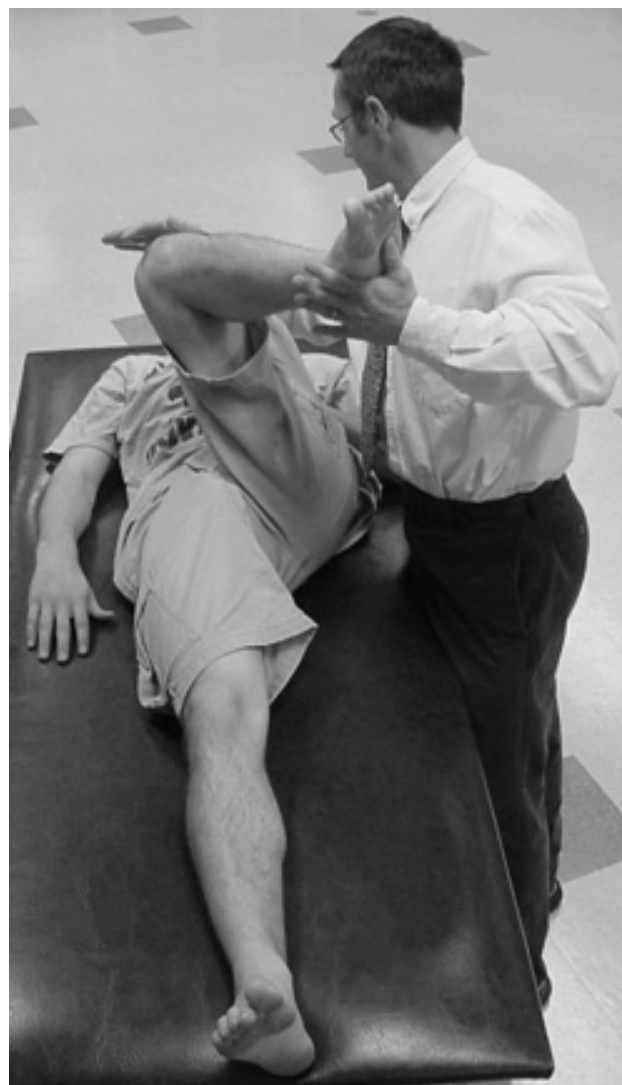flexion and was further increased by internal rotation. In this study, all 19 subjects who underwent surgery for FAI had a positive preoperative impingement test and evidence of impingement during surgery. Similar findings have been reported by Ito et al,<sup>33</sup> as 24 out of 25 individuals with arthroscopically confirmed FAI and labral tears had a positive flexion internal rotation impingement test. However, Narvani et al<sup>58</sup> reported only limited usefulness of this test (sensitivity, 75%; specificity, 43%) in identifying individuals with a labral tear diagnosed by MRA. An impingement test can also be performed with full hip extension and external rotation. Although less common, this test can cause impingement of the posterior labrum.<sup>43</sup>

Assessment for general ligament laxity, the log roll test, and long-axis femoral distraction are methods that we use to evaluate for hip laxity. General ligament laxity may predispose an individual to symptomatic hip instability. We use Beighton's scale for hypermobility to assess general ligament laxity.<sup>6</sup> This scale includes assessing opposition of the thumb to forearm, elbow hyperextension, knee hyperextension, extension of the fifth metacarpophalangeal joint, and the ability to rest the palms on the floor with straight knees.

The log roll test is performed with the patient supine.<sup>64</sup> With the hip in a neutral flexion/extension and abduction/adduction position, the patient's leg is passively rolled into full internal and external rotation. Here we evaluate side-to-side range of motion differences and clicking. In our experience, a click reproduced during this test is suggestive of a labral tear, while increased external rotation range of motion may indicate iliofemoral ligament laxity. The potential for muscle guarding and possible false-negative results must be recognized with this test.

Long-axis femoral distraction assesses change in symptoms and relative motion. Distraction is produced by the clinician leaning backward while holding the patient's leg around the malleoli, with the involved hip in 30° flexion, 30° abduction, and 10° to 15° external rotation.<sup>38</sup> We have found that an individual with capsular laxity may have increased motion and a feeling of apprehension with this maneuver. Comparatively, an individual with hypomobility may have decreased motion and relief of pain. Similar to the log roll test, potential muscle guarding and possible false-negative results for individuals with laxity can occur. Although we find these tests for hip laxity useful, published clinic studies need to be done to validate the results of these tests.

In addition to evaluating for FAI and capsular laxity, assessing hip range of motion can be used to identify individuals with diffuse articular cartilage degeneration associated with osteoarthritis. Birrell et al<sup>8</sup> found that a restriction in any single hip motion (flexion, external rotation, or internal rotation) had



**FIGURE 5.** The flexion, internal rotation, adduction femoral acetabular impingement test.

a sensitivity, specificity, and positive likelihood ratio of 86%, 54%, and 1.9, respectively, for identifying individuals with mild to moderate radiographic osteoarthritis. Limited hip internal rotation range of motion was found to be the most predictive finding of mild to moderate osteoarthritis, with a positive likelihood ratio of 3.6.<sup>8</sup> Altman et al<sup>2</sup> found that individuals with hip pain and hip internal rotation range of motion greater than or equal to 15° who experienced pain with internal rotation, had morning stiffness greater than or equal to 60 minutes, and were 50 years of age or older could be identified as having hip osteoarthritis with 86% sensitivity and 75% specificity. Altman et al<sup>2</sup> also found individuals could be classified as having osteoarthritis with a sensitivity and specificity of 86% and 75%, respectively, if hip internal rotation range of motion was less than 15° and hip flexion was less than or equal to 115°.

**TABLE 1.** A summary of the common symptoms and clinical examination findings associated with extra-articular and intra-articular sources of hip pain.

	Common Symptoms	Clinical Examination
Extra-articular pathology	<ul style="list-style-type: none"> <li>• Superficial groin, lateral hip, or posterior hip pain</li> <li>• Lateral or anterior snapping</li> </ul>	<ul style="list-style-type: none"> <li>• Tenderness to palpation</li> <li>• Pain with stretching and/or resistance to involved structures</li> </ul>
Intra-articular pathology	<ul style="list-style-type: none"> <li>• Groin pain</li> <li>• Clicking, giving way</li> </ul>	<ul style="list-style-type: none"> <li>• Groin pain/limited ROM FABER test</li> <li>• Groin pain and/or clicking with the scour test</li> <li>• Groin pain with the straight leg raise test</li> </ul>
Femoral acetabular impingement	<ul style="list-style-type: none"> <li>• Anterior pinching pain with sitting</li> </ul>	<ul style="list-style-type: none"> <li>• Anterior pinching pain with the impingement test</li> </ul>
Degenerative changes	<ul style="list-style-type: none"> <li>• Medial thigh pain</li> <li>• Morning stiffness</li> </ul>	<ul style="list-style-type: none"> <li>• Painful and/or limited internal rotation ROM</li> <li>• Limited flexion ROM</li> </ul>
Capsular laxity	<ul style="list-style-type: none"> <li>• Instability</li> </ul>	<ul style="list-style-type: none"> <li>• General hypermobility with Beighton's scale</li> <li>• Increased external rotation ROM with the leg roll test</li> <li>• Increased motion and/or apprehension with long-axis femoral distraction</li> </ul>

Abbreviation: ROM, range of motion.

### Examination for Extra-articular Pathology

In addition to assessing intra-articular structures, extra-articular structures should also be addressed, because conditions can coexist. Palpation may provide useful information regarding the contribution of extra-articular symptoms. Consistent with our experience, if the source of pain is solely from intra-articular origin, palpable pain is rarely present.<sup>36</sup> We have found that individuals with muscle strains and/or tendonitis have pain with palpation, stretching, and resisted movements directed at the involved muscle and/or tendon.

### Examination of Extrinsic Causes of Hip Pain

Examination of the lumbar spine and pelvis may be required in an individual with hip pain and a potential labral tear. Cibulka and Delitto<sup>17</sup> found that young athletes with anterior or lateral hip pain and positive signs for sacroiliac joint dysfunction responded to mobilization directed at the sacroiliac joint. Many evaluation techniques to assess the lumbopelvic area have been described. Examples of such techniques include measuring lumbar range of motion, palpating pelvic landmarks, measuring hip internal rotation range of motion, and performing the sacroiliac joint standing flexion, supine versus long sit, prone knee flexion, and FABER tests. Support for the reliability and/or validity of these procedures varies.<sup>16</sup> Brown et al<sup>11</sup> found the presence of a limp, groin pain, and limited hip internal rotation range of motion useful for distinguishing between individuals with a hip disorder or hip and spine

disorder from a spine-only disorder. Positive likelihood ratios for the presence of these 3 findings in identifying individuals with hip problems or hip and spine problems from individuals with spine problems were 7, 7, and 14, respectively. If tests are positive for a lumbopelvic disorder, treatment may be directed there and its effect on hip pain can be evaluated.

### Summary of Clinical Assessment Findings

Table 1 summarizes common symptoms and clinical exam findings that are associated with intra-articular and extra-articular sources of hip pain. Studies that have examined the usefulness of patient symptoms and clinical examination results are summarized in Tables 2 and 3, respectively. Because there is lack of well-designed studies available to substantiate the reliability and validity of many of the findings described, further research is needed in this area to allow these tests to be more accurately interpreted.

### DIFFERENTIAL DIAGNOSIS

There are many causes for hip pain (Table 4). Comprehensive reviews for differential diagnosis related to the hip are available.<sup>1,9,50,69,72,73</sup> There are a number of "red flags" that must not be overlooked. Acute hip pain with fever, malaise, night sweats, weight loss, night pain, intravenous drug abuse, history of cancer and/or compromised immune system may be indicative of tumor, infection, septic arthritis, osteomyelitis or an inflammatory condition. A fracture should be considered if there is history of significant trauma, pain occurring with any and all



**TABLE 2.** Summary of studies providing information that may be used to interpret the symptoms of an individual with a potential acetabular labral tear.

Authors	Summary of Study Findings	Characteristics of Subjects	
Keeney et al <sup>35</sup>	<ul style="list-style-type: none"> <li>Groin pain is the most common location of reported pain in individuals with a labral tear</li> <li>The presence of locking or catching may not be sensitive for labral tears</li> </ul>	<ul style="list-style-type: none"> <li>Pain location: groin (n = 97, 96%); anterior hip (n = 35, 34.5%); lateral hip (n = 38, 37.6%); buttock (n = 17, 16.8%)</li> <li>58% of individuals with a labral tear reported hip locking or catching</li> </ul>	<ul style="list-style-type: none"> <li>101 individuals (102 hips) with clinically diagnosed labral tears (93 were confirmed during arthroscopic surgery)</li> <li>Mean age, 37.6 y</li> <li>Female, n = 71 (69.6%); male, n = 31 (30.4%)</li> <li>MDS, 21.6 mo (range, 3-120 mo)</li> </ul>
McCarthy and Busconi <sup>54</sup>	<ul style="list-style-type: none"> <li>Groin pain may indicate not only a labral tear but the presence of intra-articular pathologies in general</li> <li>Inguinal clicking and giving way correlated to the presence of a labral tear</li> </ul>	<ul style="list-style-type: none"> <li>100% of individuals with a labral tear reported groin pain</li> <li>98% of all individuals with intra-articular pathology reported groin pain</li> <li>Respectively, <math>r = 0.79</math>, <math>P &lt; .0005</math>, and <math>r = 0.41</math>, <math>P &lt; .002</math></li> </ul>	<ul style="list-style-type: none"> <li>94 individuals who underwent arthroscopic surgery (labral tear, n = 35; loose bodies, n = 23; chondral defect, n = 16; degenerative joint disease, n = 18; synovitis, n = 40)</li> <li>Mean age, 37 y (range, 17-69 y)</li> <li>Female, 50 y (53.2%); male, 44 y (46.8%)</li> <li>MDS, 2.6 y (range, 0.5-9.5 y)</li> </ul>
Narvani et al <sup>58</sup>	<ul style="list-style-type: none"> <li>The presence or absence of clicking in the hip may provide useful diagnostic information</li> </ul>	<ul style="list-style-type: none"> <li>Clicking in the hip had 100% sensitivity, 85% specificity, and positive likelihood ratio of 6.67 for a labral tear</li> </ul>	<ul style="list-style-type: none"> <li>18 individuals with groin pain who were diagnosed by magnetic resonance arthrogram (labral tear, n = 4; extra-articular pathology, n = 8; normal, n = 6)</li> <li>Mean age, 31 y (range, 17-48 y)</li> <li>Female, n = 5; males, n = 13</li> <li>MDS, 9 wk (range, 4-16 wk)</li> </ul>

Abbreviations: MDS, mean duration of symptoms.

movement, inability to walk and bear weight through the extremity, and/or in the presence of a shortened externally rotated lower extremity. A history of corticosteroid exposure or alcohol abuse may put an individual at risk for avascular necrosis.<sup>50</sup> A careful history and examination needs to be done to screen for conditions that require consultation to other healthcare professionals. Additional diagnostic laboratory or imaging may be necessary to determine the exact cause of symptoms.<sup>10,74</sup>

## DIAGNOSTIC TESTING

Diagnostic testing for hip pain can include imaging, as well as intra-articular injections. Gadolinium-enhanced MRA is thought to be the diagnostic imaging of choice when evaluating for acetabular labral tears.<sup>36</sup> Sensitivity and specificity values range from 66% to 95% and 71% to 88% for MRA in diagnosing labral tears.<sup>12,18,19,20,54,61</sup> Conventional magnetic resonance imaging (MRI) may not be as reliable as MRA in detecting labral tears. Byrd and Jones<sup>12</sup> found MRI to have sensitivity and specificity values of 25% and 67% compared to 66% and 75% for MRA. This retrospective study compared MRI and

MRA with surgical findings in 40 individuals with multiple pathologies. The 3 most common findings in this study were labral tears (n = 32), chondral damage (n = 22), and disruption of the ligamentum teres (n = 7). Although there is information regarding the sensitivity and specificity of MRA in diagnosing labral tears, likelihood ratios have not been provided.

In addition to MRI and MRA, other diagnostic testing can include plain radiograph, radionuclide bone scan, computed tomography (CT) scan, ultrasound, and intra-articular injection. Plain radiographs are not helpful in diagnosing a labral tear.<sup>12,54</sup> However, they can be used to evaluate bony abnormalities which may contribute to labral tears.<sup>75</sup> This includes hip dysplasia, as seen in Figure 6. The center edge angle of Wiberg is commonly measured to assess for dysplasia of the acetabulum. Anterior asphericity of the femoral head, lack of femoral head-neck offset (Figure 7) and retroversion of the acetabulum are used to assess for potential FAI.<sup>26,75</sup> The radiographic presence of osteophytes (femoral or acetabular) and joint space narrowing (superior, axial, and/or medial) have been used to assess for articular cartilage degeneration. An example of an individual that



**TABLE 3.** Summary of studies providing information that may be used to interpret clinical examination findings in the diagnosis of acetabular labral tear.

Author	Summary of Study Findings	Characteristic of Subjects
Brown et al <sup>11</sup>	<ul style="list-style-type: none"> <li>• Limping, groin pain, and limited hip IR ROM can be useful in distinguishing between individuals with a hip disorder or hip and spine disorder from a spine-only disorder</li> </ul>	<ul style="list-style-type: none"> <li>• Positive likelihood ratios: presence of a limp, 7; groin pain, 7; limited IR ROM, 14</li> </ul>
Mitchell et al <sup>57</sup>	<ul style="list-style-type: none"> <li>• FABER test with reproduction of hip pain was sensitive for identifying individuals with a labral tear</li> </ul>	<ul style="list-style-type: none"> <li>• 95 individuals diagnosed using imaging studies (hip disorders, n = 43; both hip and spine disorders, n = 34; spine only, n = 18)</li> </ul>
Narvani et al <sup>58</sup>	<ul style="list-style-type: none"> <li>• Sensitivity, 88%</li> </ul>	<ul style="list-style-type: none"> <li>• 25 individuals who underwent hip arthroscopy (labral tear, n = 17; detached labrum, n = 5; frayed labrum, n = 2; chondral lesion, n = 14; loose bodies, n = 2; synovitis, n = 3)</li> </ul>
Birrell et al <sup>8</sup>	<ul style="list-style-type: none"> <li>• Impingement test without reproduction of hip pain may be helpful to rule out the diagnosis of a labral tear</li> </ul>	<ul style="list-style-type: none"> <li>• Hip pain with impingement test: sensitivity, 75%; specificity, 43%</li> </ul>
Altman et al <sup>2</sup>	<ul style="list-style-type: none"> <li>• Hip ROM may be helpful to rule out individuals with mild to moderate osteoarthritis</li> </ul>	<ul style="list-style-type: none"> <li>• Restricted hip ROM in any single plane: sensitivity, 85%; specificity, 54%; positive likelihood ratio, 1.9</li> </ul>
	<ul style="list-style-type: none"> <li>• Characteristics of individuals with osteoarthritis: painful hip IR ROM, <math>\geq 15^\circ</math>; morning hip stiffness, <math>\geq 60</math> min; age, <math>\geq 50</math> y</li> <li>• IR ROM <math>&lt; 15^\circ</math> and flexion <math>\leq 115^\circ</math></li> </ul>	<ul style="list-style-type: none"> <li>• Sensitivity, 86%; specificity, 75%</li> <li>• Sensitivity, 86%; specificity, 75%</li> </ul>
		<ul style="list-style-type: none"> <li>• 18 individuals with groin pain who were diagnosed by magnetic resonance arthrogram (labral tear, n = 4; extra-articular pathology, n = 8; normal, n = 6)</li> </ul>
		<ul style="list-style-type: none"> <li>• 195 individuals with "new episodes of hip pain with and without radiographic evidence of osteoarthritis"</li> </ul>
		<ul style="list-style-type: none"> <li>• Mean age, 67.5 y (range, 30-84 y)</li> <li>• Females, n = 61; males, n = 34</li> </ul>
		<ul style="list-style-type: none"> <li>• Mean age, 30.9 y (range, 16-56 y)</li> <li>• Females, n = 9; male, n = 16</li> <li>• MDS, 3 y (range, .3-10 y)</li> </ul>
		<ul style="list-style-type: none"> <li>• Mean age, 31 y (range, 17-48 y)</li> <li>• Female, n = 5; males, n = 13</li> <li>• MDS, 9 wk (range, 4-16 wk)</li> </ul>
		<ul style="list-style-type: none"> <li>• Mean age, 63 y</li> <li>• Females, 132; males, 63</li> <li>• Duration of symptoms, <math>&lt; 12</math> mo</li> </ul>
		<ul style="list-style-type: none"> <li>• 114 individuals with osteoarthritis</li> <li>• 87 control subjects (rheumatoid arthritis, n = 37; sciatic radiculopathy, n = 11; spondylarthropathy, n = 9; trochanteric bursitis, n = 9; non-articular rheumatism, n = 9; avascular necrosis, n = 4; fracture, n = 3; other, n = 5)</li> </ul>
		<ul style="list-style-type: none"> <li>• Individuals with osteoarthritis: mean <math>\pm</math> SD age, <math>64 \pm 13</math> y; females, n = 43; males, n = 71</li> <li>• Control subjects: mean age, <math>57 \pm 15</math> y; females, n = 28; males, n = 59</li> </ul>

Abbreviation: MDS, mean duration of symptoms; IR, internal rotation; ROM, range of motion; SD, standard deviation.

presented with radiographic evidence of an acetabular osteophyte, femoral osteophyte, and joint space narrowing is presented in Figure 8. Altman et al<sup>2</sup> reported that the radiographic presence of osteophytes separated individuals with osteoarthritis from controls with a sensitivity of 89% and a specificity of 91%.

As with plain radiographs, bone scan, CT, ultrasound, and intra-articular injection are not used to diagnose labral tears. A bone scan gives poor anatomical resolution but is used to assess local blood

flow and osteogenic activity. It is sensitive to fractures, arthritis, neoplasms, infections, and vascular abnormalities.<sup>36</sup> Conventional CT is used to assess for bone abnormalities, while ultrasound is helpful for evaluating soft tissue and intra-articular effusion.<sup>36</sup> An intra-articular injection uses an anesthetic to help confirm an intra-articular pathology. Byrd and Jones<sup>12</sup> found that an intra-articular injection was 90% accurate in detecting the presence of intra-articular abnormality. The information presented on diagnostic testing related to labral tears is summarized in Table 5.

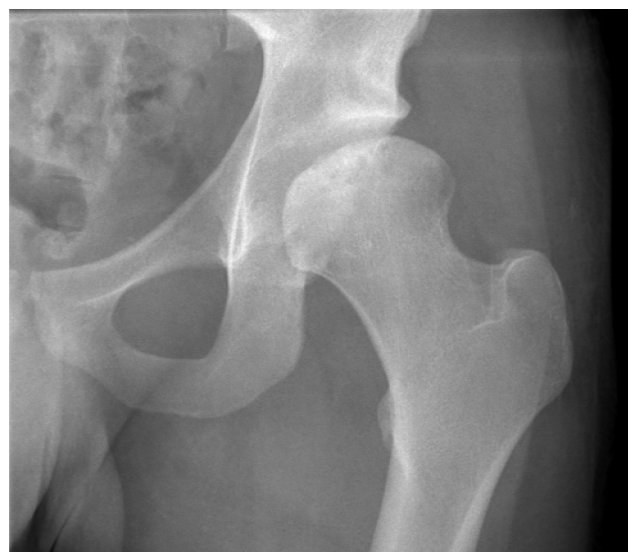## CONCLUSION

The relationship between anatomical pathology and the clinical examination of individuals with suspected acetabular labral tears is not well understood. Emerging evidence suggests that information obtained from patient history and clinical examina-

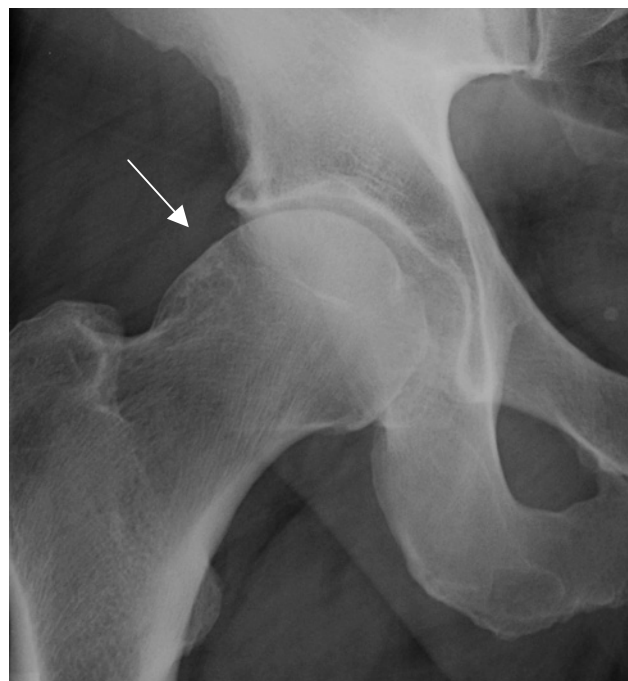tion can be used to identify individuals with potential labral tears; however, there is substantial overlap with other hip disorders. The hip examination should include screening the lumbosacral spine and an evaluation of intra-articular and extra-articular structures to narrow down the alleged pathology. If a labral tear is suspected, associated factors such as hypermobility, FAI, and hypomobility should be considered. In addition, MRA may be necessary to establish the diagnosis of an acetabular labral tear. Continued research is warranted to determine the diagnostic accuracy of many of our examination techniques.

**TABLE 4.** Potential causes of hip pain.

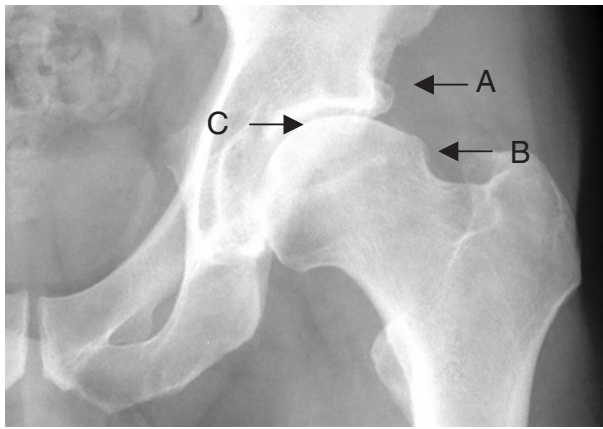
Articular cartilage
• Chondral lesion
• Osteoarthritis
Childhood disorders
• Congenital dysplasia
• Legg-Calvé-Perthes disease
• Slipped capital femoral epiphysis
Inflammation
• Trochanteric bursitis
• Psoas bursitis
• Tendonitis
• Toxic synovitis
Infection
• Septic arthritis
• Osteomyelitis
Labral tear
Neoplasm
Neurologic
• Local nerve entrapment
Overuse
• Stress fractures of the femur
• Muscle strains
• Inguinal hernia
• Femoral hernia
Referred
• Lumbar disc pathology
• Lumbar spine degenerative joint disease
• Athletic pubalgia
• Radiculopathy
• Piriformis syndrome
• Sacroiliac joint pathology
• Genitourinary tract pathology
• Abdominal wall pathology
Systemic
• Rheumatoid arthritis
• Crohn's disease
• Psoriasis
• Reiter's syndrome
• Systemic lupus erythematosus
Trauma
• Soft-tissue contusion
• Fractures of the femoral head
• Dislocation of the femoral head
• Avulsion injury
• Myositis ossificans
Vascular
• Avascular necrosis
• Osteonecrosis



**FIGURE 6.** Radiographic evidence of hip dysplasia.



**FIGURE 7.** A radiograph demonstrating a lack of femoral head-neck offset.



**FIGURE 8.** Radiograph demonstrating (A) acetabular osteophyte, (B) femoral osteophyte, and (C) joint space narrowing.

**TABLE 5.** Potential uses for diagnostic imaging in individuals with hip symptoms.

Diagnostic Test	Potential Uses
Magnetic resonance imaging	Acetabular labral tear
Magnetic resonance arthrography	Acetabular labral tear
Plain radiographs	Bony abnormalities including dysplasia and femoral acetabular impingement, osteophytes, joint space narrowing, articular cartilage degeneration, and fractures
Bone scan	Fractures, arthritis, neoplasm, infections, and vascular abnormalities
Computed tomography (CT) scan	Bone abnormalities
Ultrasound	Soft tissue and intra-articular effusion
Intra-articular injection	Confirm an intra-articular pathology

**REFERENCES**

1. Adkins SB, 3rd, Figler RA. Hip pain in athletes. *Am Fam Physician.* 2000;61:2109-2118.
2. Altman R, Alarcon G, Appelrouth D, et al. The American College of Rheumatology criteria for the classification and reporting of osteoarthritis of the hip. *Arthritis Rheum.* 1991;34:505-514.
3. Baber YF, Robinson AH, Villar RN. Is diagnostic arthroscopy of the hip worthwhile? A prospective review of 328 adults investigated for hip pain. *J Bone Joint Surg Br.* 1999;81:600-603.
4. Beck M, Kalhor M, Leunig M, Ganz R. Hip morphology influences the pattern of damage to the acetabular cartilage: femoroacetabular impingement as a cause of

- early osteoarthritis of the hip. *J Bone Joint Surg Br.* 2005;87:1012-1018.
5. Beck M, Leunig M, Parvizi J, Boutier V, Wyss D, Ganz R. Anterior femoroacetabular impingement: part II. Mid-term results of surgical treatment. *Clin Orthop Relat Res.* 2004;67-73.
6. Beighton P, Solomon L, Soskolne CL. Articular mobility in an African population. *Ann Rheum Dis.* 1973;32:413-418.
7. Bellabarba C, Sheinkop MB, Kuo KN. Idiopathic hip instability. An unrecognized cause of coxa saltans in the adult. *Clin Orthop Relat Res.* 1998;261-271.
8. Birrell F, Croft P, Cooper C, Hosie G, Macfarlane G, Silman A. Predicting radiographic hip osteoarthritis from range of movement. *Rheumatology (Oxford).* 2001;40:506-512.
9. Boyd KT, Peirce NS, Batt ME. Common hip injuries in sport. *Sports Med.* 1997;24:273-288.
10. Browder DA, Erhard RE. Decision making for a painful hip: a case requiring referral. *J Orthop Sports Phys Ther.* 2005;35:738-744.
11. Brown MD, Gomez-Marin O, Brookfield KF, Li PS. Differential diagnosis of hip disease versus spine disease. *Clin Orthop Relat Res.* 2004;280-284.
12. Byrd JW, Jones KS. Diagnostic accuracy of clinical assessment, magnetic resonance imaging, magnetic resonance arthrography, and intra-articular injection in hip arthroscopy patients. *Am J Sports Med.* 2004;32:1668-1674.
13. Byrd JW, Jones KS. Hip arthroscopy in athletes. *Clin Sports Med.* 2001;20:749-761.
14. Byrd JW, Jones KS. Hip arthroscopy in the presence of dysplasia. *Arthroscopy.* 2003;19:1055-1060.
15. Byrd JW, Jones KS. Traumatic rupture of the ligamentum teres as a source of hip pain. *Arthroscopy.* 2004;20:385-391.
16. Childs JD, Fritz JM, Piva SR, Erhard RE. Clinical decision making in the identification of patients likely to benefit from spinal manipulation: a traditional versus an evidence-based approach. *J Orthop Sports Phys Ther.* 2003;33:259-272.
17. Cibulka MT, Delitto A. A comparison of two different methods to treat hip pain in runners. *J Orthop Sports Phys Ther.* 1993;17:172-176.
18. Czerny C, Hofmann S, Neuhold A, et al. Lesions of the acetabular labrum: accuracy of MR imaging and MR arthrography in detection and staging. *Radiology.* 1996;200:225-230.
19. Czerny C, Hofmann S, Urban M, et al. MR arthrography of the adult acetabular capsular-labral complex: correlation with surgery and anatomy. *AJR Am J Roentgenol.* 1999;173:345-349.
20. Czerny C, Kramer J, Neuhold A, Urban M, Tschauner C, Hofmann S. [Magnetic resonance imaging and magnetic resonance arthrography of the acetabular labrum: comparison with surgical findings]. *ROFO.* 2001;173:702-707.
21. Dall D, Macnab I, Gross A. Recurrent anterior dislocation of the hip. *J Bone Joint Surg Am.* 1970;52:574-576.
22. Dameron TB, Jr. Bucket-handle tear of acetabular labrum accompanying posterior dislocation of the hip. *J Bone Joint Surg Am.* 1959;41-A:131-134.
23. Dobbs MB, Gordon JE, Luhmann SJ, Szymanski DA, Schoenecker PL. Surgical correction of the snapping iliopsoas tendon in adolescents. *J Bone Joint Surg Am.* 2002;84-A:420-424.
24. Dorfmann H, Boyer T. Arthroscopy of the hip: 12 years of experience. *Arthroscopy.* 1999;15:67-72.
25. Dorrell JH, Catterall A. The torn acetabular labrum. *J Bone Joint Surg Br.* 1986;68:400-403.

26. Eijer H, Myers SR, Ganz R. Anterior femoroacetabular impingement after femoral neck fractures. *J Orthop Trauma*. 2001;15:475-481.
27. Ferguson SJ, Bryant JT, Ganz R, Ito K. An in vitro investigation of the acetabular labral seal in hip joint mechanics. *J Biomech*. 2003;36:171-178.
28. Ferguson SJ, Bryant JT, Ganz R, Ito K. The influence of the acetabular labrum on hip joint cartilage consolidation: a poroelastic finite element model. *J Biomech*. 2000;33:953-960.
29. Fitzgerald RH, Jr. Acetabular labrum tears. Diagnosis and treatment. *Clin Orthop Relat Res*. 1995;60-68.
30. Ganz R, Parvizi J, Beck M, Leunig M, Notzli H, Siebenrock KA. Femoroacetabular impingement: a cause for osteoarthritis of the hip. *Clin Orthop Relat Res*. 2003;112-120.
31. Hickman JM, Peters CL. Hip pain in the young adult: diagnosis and treatment of disorders of the acetabular labrum and acetabular dysplasia. *Am J Orthop*. 2001;30:459-467.
32. Iida H, Kaneda E, Takada H, Uchida K, Kawanabe K, Nakamura T. Metallosis due to impingement between the socket and the femoral neck in a metal-on-metal bearing total hip prosthesis. A case report. *J Bone Joint Surg Am*. 1999;81:400-403.
33. Ito K, Leunig M, Ganz R. Histopathologic features of the acetabular labrum in femoroacetabular impingement. *Clin Orthop Relat Res*. 2004;262-271.
34. Ito K, Minka MA, 2nd, Leunig M, Werlen S, Ganz R. Femoroacetabular impingement and the cam-effect. A MRI-based quantitative anatomical study of the femoral head-neck offset. *J Bone Joint Surg Br*. 2001;83:171-176.
35. Keeney JA, Peelle MW, Jackson J, Rubin D, Maloney WJ, Clohisy JC. Magnetic resonance arthrography versus arthroscopy in the evaluation of articular hip pathology. *Clin Orthop Relat Res*. 2004;163-169.
36. Kelly BT, Williams RJ, 3rd, Philippon MJ. Hip arthroscopy: current indications, treatment options, and management issues. *Am J Sports Med*. 2003;31:1020-1037.
37. Kim YT, Azuma H. The nerve endings of the acetabular labrum. *Clin Orthop Relat Res*. 1995;176-181.
38. Kisner C, Colby LA. *Therapeutic Exercise: Foundation and Techniques*. Philadelphia, PA: F.A. Davis; 2002.
39. Klaue K, Durnin CW, Ganz R. The acetabular rim syndrome. A clinical presentation of dysplasia of the hip. *J Bone Joint Surg Br*. 1991;73:423-429.
40. Kobayashi S, Takaoka K, Tsukada A, Ueno M. Polyethylene wear from femoral bipolar neck-cup impingement as a cause of femoral prosthetic loosening. *Arch Orthop Trauma Surg*. 1998;117:390-391.
41. Lage LA, Patel JV, Villar RN. The acetabular labral tear: an arthroscopic classification. *Arthroscopy*. 1996;12:269-272.
42. Lavigne M, Parvizi J, Beck M, Siebenrock KA, Ganz R, Leunig M. Anterior femoroacetabular impingement: part I. Techniques of joint preserving surgery. *Clin Orthop Relat Res*. 2004;61-66.
43. Leunig M, Beck M, Dora C, Ganz R. Femoroacetabular impingement: etiology and surgical concept. *Oper Tech Orthop*. 2005;15:247-255.
44. Leunig M, Beck M, Kalhor M, Kim YJ, Werlen S, Ganz R. Fibrocystic changes at anterosuperior femoral neck: prevalence in hips with femoroacetabular impingement. *Radiology*. 2005;236:237-246.
45. Leunig M, Beck M, Woo A, Dora C, Kerboul M, Ganz R. Acetabular rim degeneration: a constant finding in the aged hip. *Clin Orthop Relat Res*. 2003;201-207.
46. Leunig M, Casillas MM, Hamlet M, et al. Slipped capital femoral epiphysis: early mechanical damage to the acetabular cartilage by a prominent femoral metaphysis. *Acta Orthop Scand*. 2000;71:370-375.
47. Lieberman JR, Altchek DW, Salvati EA. Recurrent dislocation of a hip with a labral lesion: treatment with a modified Bankart-type repair. Case report. *J Bone Joint Surg Am*. 1993;75:1524-1527.
48. MacDonald SJ, Garbuz D, Ganz R. Clinical evaluation of the symptomatic young adult hip. *Semin Arthroplasty*. 1997;8:3-9.
49. Magee DJ. *Orthopedic Physical Assessment*. Philadelphia, PA: W.B. Saunders; 1992.
50. Margo K, Drezner J, Motzkin D. Evaluation and management of hip pain: an algorithmic approach. *J Fam Pract*. 2003;52:607-617.
51. Martin RL, Kelly BT, Philippon MJ. A classification system for labral tears of the hip [abstract]. *J Orthop Sports Phys Ther*. 2005;35:A23.
52. Mason JB. Acetabular labral tears in the athlete. *Clin Sports Med*. 2001;20:779-790.
53. McCarthy J, Noble P, Aluisio FV, Schuck M, Wright J, Lee JA. Anatomy, pathologic features, and treatment of acetabular labral tears. *Clin Orthop Relat Res*. 2003;38-47.
54. McCarthy JC, Busconi B. The role of hip arthroscopy in the diagnosis and treatment of hip disease. *Orthopedics*. 1995;18:753-756.
55. McCarthy JC, Noble PC, Schuck MR, Wright J, Lee J. The Otto E. Aufranc Award: The role of labral lesions to development of early degenerative hip disease. *Clin Orthop Relat Res*. 2001;25-37.
56. McCarthy JC, Noble PC, Schuck MR, Wright J, Lee J. The watershed labral lesion: its relationship to early arthritis of the hip. *J Arthroplasty*. 2001;16:81-87.
57. Mitchell B, McCrory P, Brukner P, O'Donnell J, Colson E, Howells R. Hip joint pathology: clinical presentation and correlation between magnetic resonance arthrography, ultrasound, and arthroscopic findings in 25 consecutive cases. *Clin J Sport Med*. 2003;13:152-156.
58. Narvani AA, Tsiridis E, Kendall S, Chaudhuri R, Thomas P. A preliminary report on prevalence of acetabular labrum tears in sports patients with groin pain. *Knee Surg Sports Traumatol Arthrosc*. 2003;11:403-408.
59. Noguchi Y, Miura H, Takasugi S, Iwamoto Y. Cartilage and labrum degeneration in the dysplastic hip generally originates in the anterosuperior weight-bearing area: an arthroscopic observation. *Arthroscopy*. 1999;15:496-506.
60. Notzli HP, Wyss TF, Stoecklin CH, Schmid MR, Treiber K, Hodler J. The contour of the femoral head-neck junction as a predictor for the risk of anterior impingement. *J Bone Joint Surg Br*. 2002;84:556-560.
61. Petersilge CA, Haque MA, Petersilge WJ, Lewin JS, Lieberman JM, Buly R. Acetabular labral tears: evaluation with MR arthrography. *Radiology*. 1996;200:231-235.
62. Philippon MJ. Debridement of acetabular labral tears with associated thermal capsulorrhaphy. *Oper Tech Orthop*. 2002;10:215-218.
63. Philippon MJ. The role of arthroscopic thermal capsulorrhaphy in the hip. *Clin Sports Med*. 2001;20:817-829.
64. Philippon MJ, Schenker ML. Athletic hip injuries and capsular laxity. *Oper Tech Orthop*. 2005;15:261-266.
65. Rao J, Zhou YX, Villar RN. Injury to the ligamentum teres. Mechanism, findings, and results of treatment. *Clin Sports Med*. 2001;20:791-799, vii.



66. Rashleigh-Belcher HJ, Cannon SR. Recurrent dislocation of the hip with a "Bankart-type" lesion. *J Bone Joint Surg Br.* 1986;68:398-399.
67. Schaberg JE, Harper MC, Allen WC. The snapping hip syndrome. *Am J Sports Med.* 1984;12:361-365.
68. Schenker ML, Martin RL, Weiland DE, Philippon MJ. Current trends in hip arthroscopy: a review of injury diagnosis, techniques and outcome scoring. *Curr Opin Orthop.* 2005;16:89-94.
69. Scopp JM, Moorman CT, 3rd. The assessment of athletic hip injury. *Clin Sports Med.* 2001;20:647-659.
70. Takechi H, Nagashima H, Ito S. Intra-articular pressure of the hip joint outside and inside the limbus. *Nippon Seikeigeka Gakkai Zasshi.* 1982;56:529-536.
71. Tanzer M, Noiseux N. Osseous abnormalities and early osteoarthritis: the role of hip impingement. *Clin Orthop Relat Res.* 2004;170-177.
72. Troum OM, Crues JV, 3rd. The young adult with hip pain: diagnosis and medical treatment, circa 2004. *Clin Orthop Relat Res.* 2004;9-17.
73. Weinstein SL. Natural history and treatment outcomes of childhood hip disorders. *Clin Orthop Relat Res.* 1997;227-242.
74. Weishaar MD, McMillian DM, Moore JH. Identification and management of 2 femoral shaft stress injuries. *J Orthop Sports Phys Ther.* 2005;35:665-673.
75. Wenger DE, Kendell KR, Miner MR, Trousdale RT. Acetabular labral tears rarely occur in the absence of bony abnormalities. *Clin Orthop Relat Res.* 2004;145-150.
76. Yamaguchi M, Akisue T, Bauer TW, Hashimoto Y. The spatial location of impingement in total hip arthroplasty. *J Arthroplasty.* 2000;15:305-313.